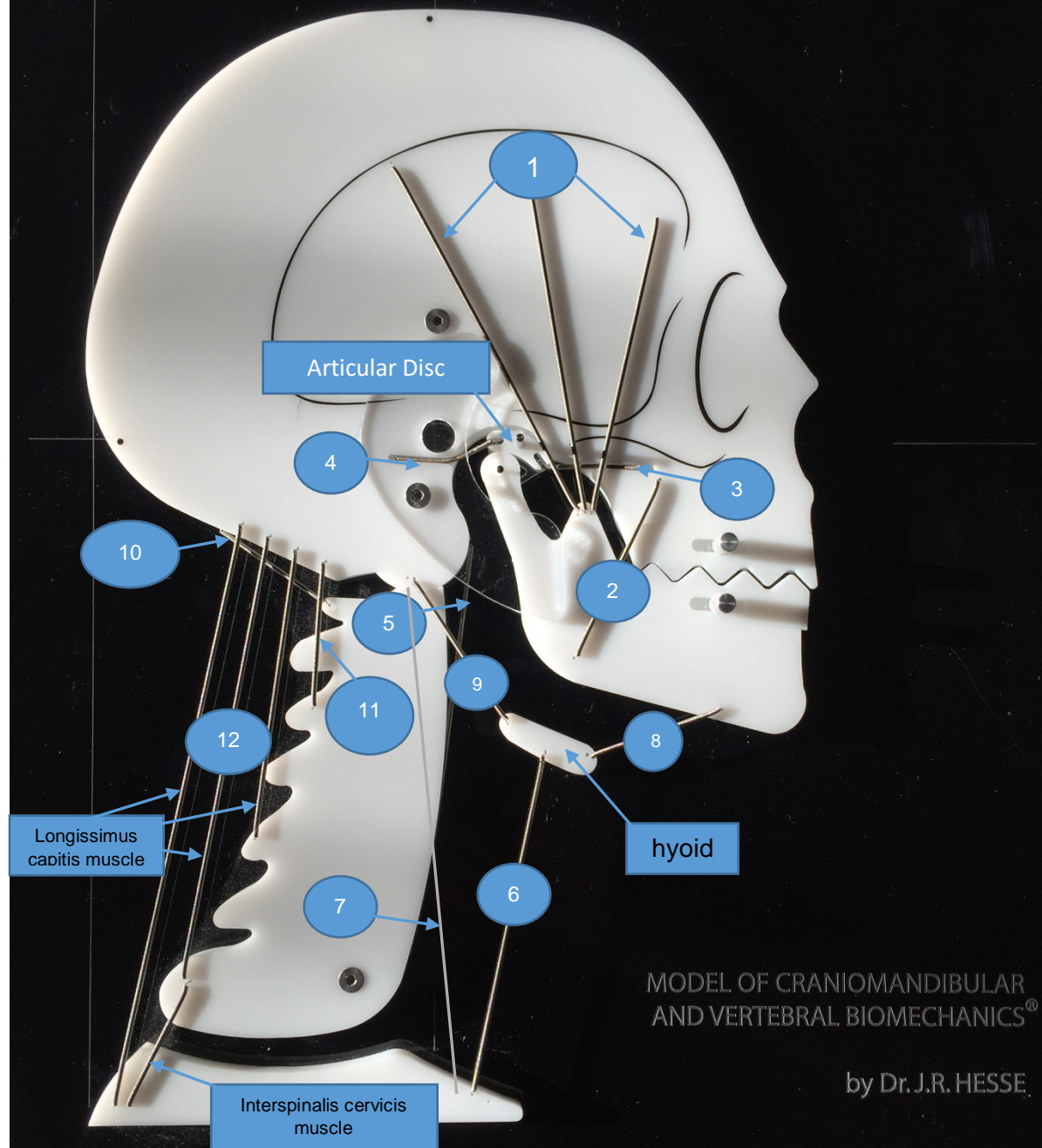


This Model can be purchased through Dr. Jules Hesse www.biomecmodels.com

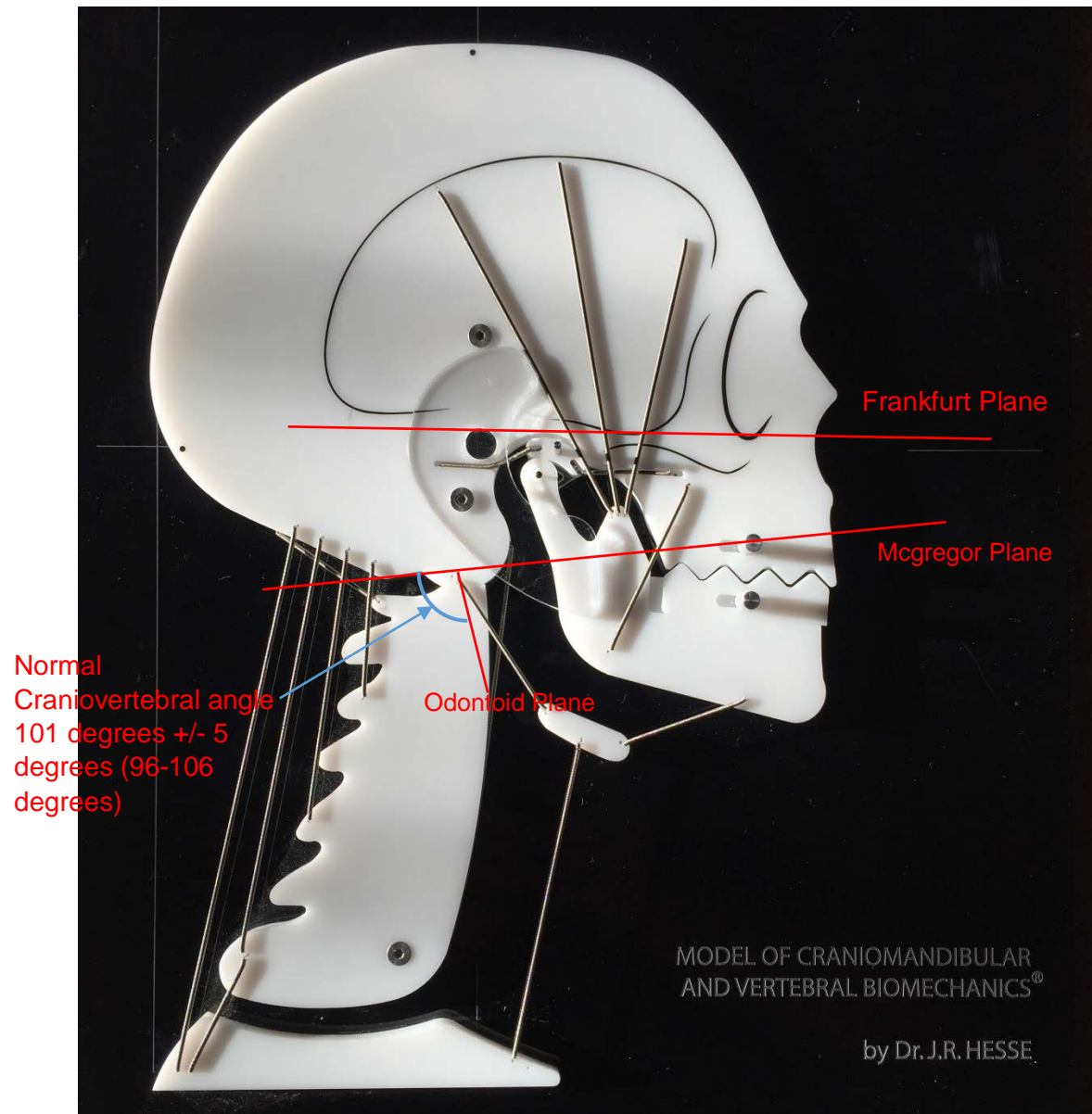


MODEL OF CRANIOMANDIBULAR
AND VERTEBRAL BIOMECHANICS®

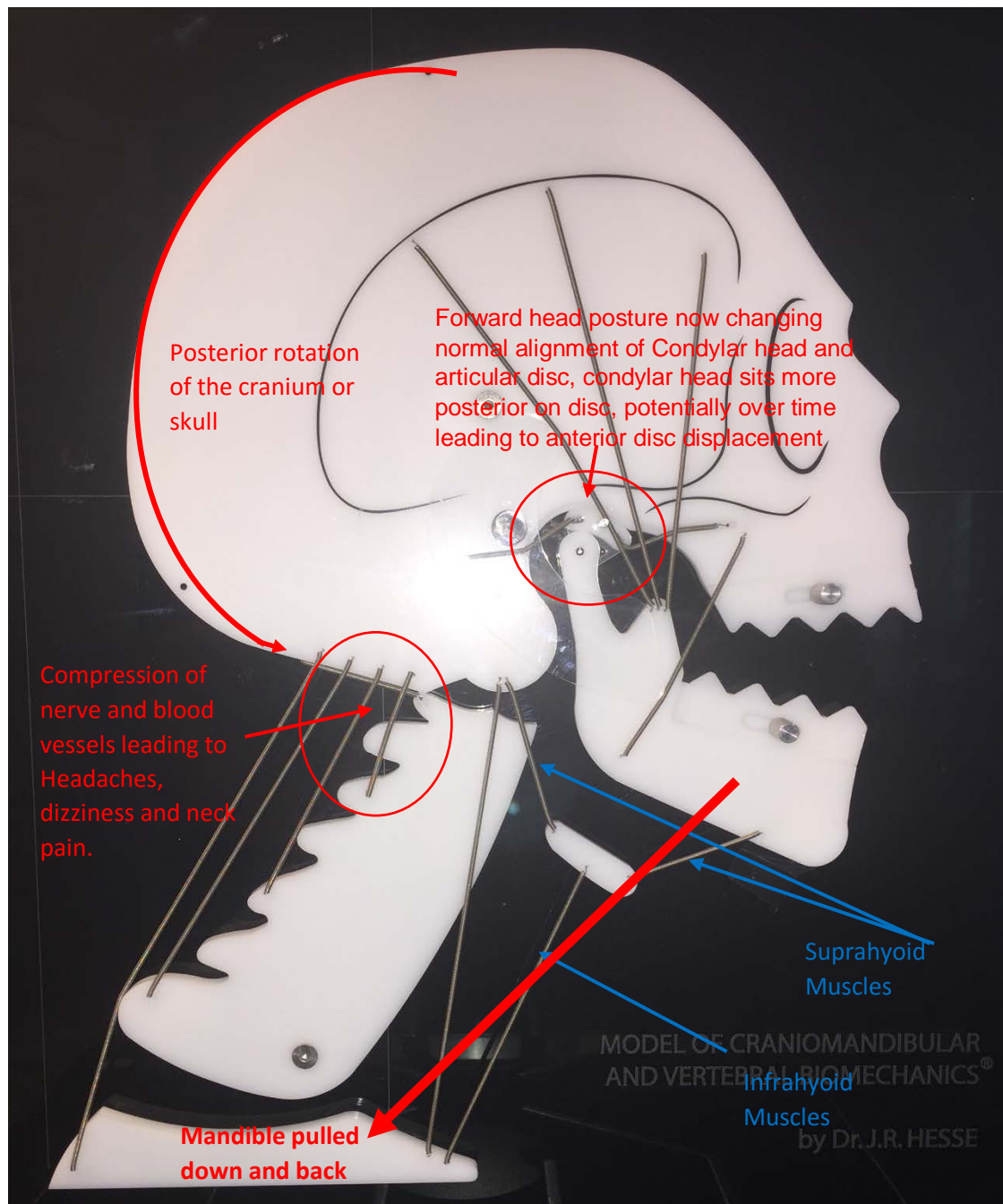
by Dr. J.R. HESSE

- | | | |
|--------------------------|----------------------------|-------------------------|
| 1 m.temporalis | 5 m.longus colli | 9 m.digastricus (post.) |
| 2 m.masseter | 6 m.sternohyoideus | 10 m.rect.cap.post.maj. |
| 3 m.pterygoid.lat.(sup.) | 7 m.sternocleidomastoideus | 11 m.semispin.capitis |
| 4 bilaminary zone | 8 m.digastricus (ant.) | 12 cervical extensors |

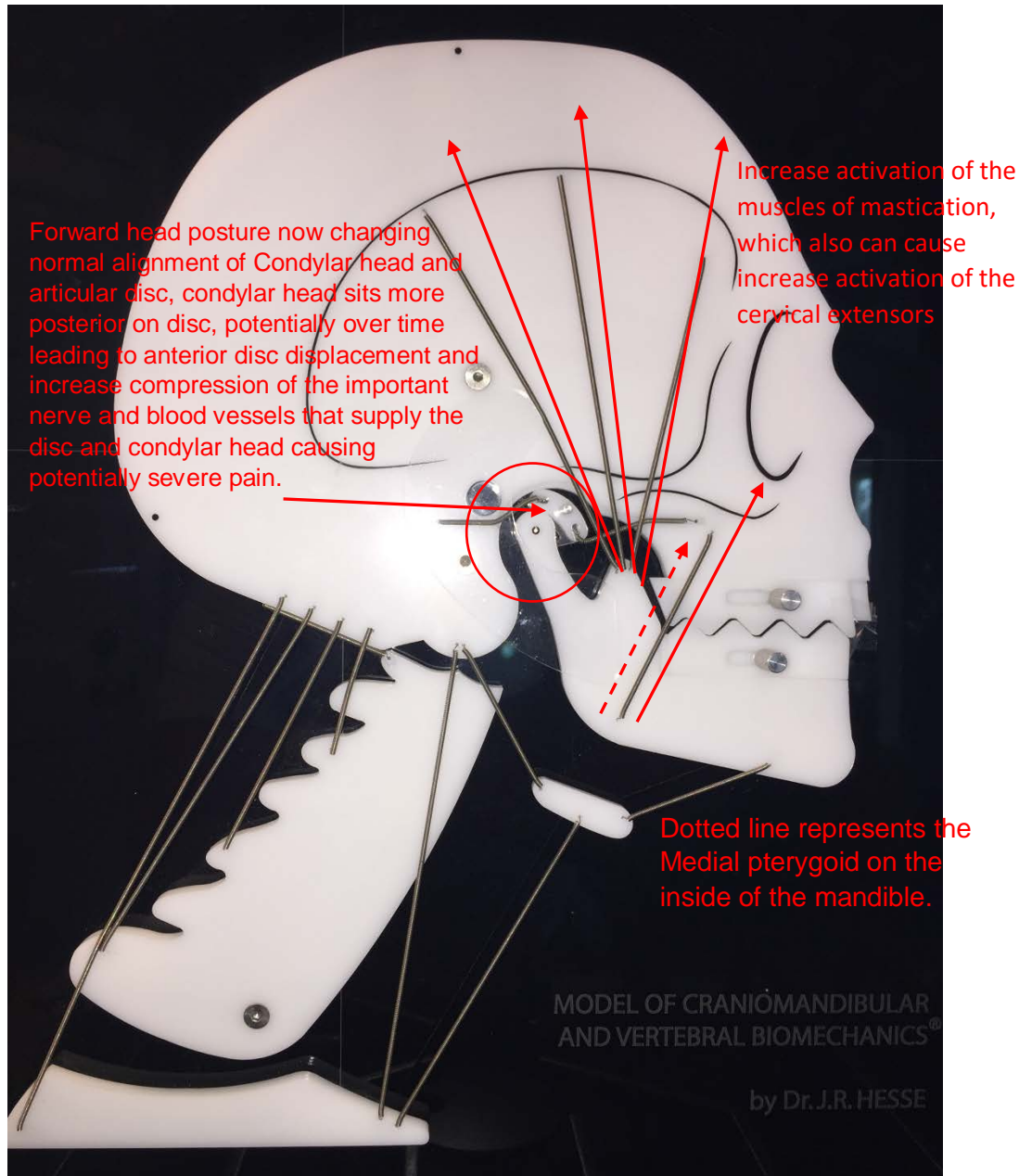
www.biomecmodels.com



The neutral or ortho-static head position (with horizontal Frankfurter plane) will allow healthy TMJ, craniocervical, cervico-thoracic functions, and a stable occlusion ('bite'). Rocabado further defined normal cervical lordosis and normal craniocervical relationships based on cephalometric measurements. A line that connects the posterior nasal spine to the basi-occiput is called the McGregor's plane. The odontoid plane (OP) is a line that extends from apex to the anterior inferior angle of the odontoid process. A normal measurement of the posterior-inferior angle (craniocervical angle -CV) at the intersection of McGregor's plane and OP is 101 degrees +/- 5 degrees (96-106 degrees). A distance between the basi-occiput to the posterior arch of the atlas is 4-9 mm (less than 4 mm indicates craniocervical compression). When we lose this normal CV angle and assume a forward head posture, we also lose our normal or healthy cervical curve or lordosis, which can potentially lead to premature cervical spine joint degeneration and of course pain.



With forward head posture we increase the distance from chin to sternum stretching the hyoid muscles, which in turn will have the tendency to pull mandible back and down. This may also lead to the development of a retro-inclined profile (the chin posteriorly set) and mandibular malformation, as the mandible is being held posteriorly during growth and development. This can also be the start of creating a disc displacement issue with the Temporomandibular joint as well as general myofascial pain of the muscles of mastication and the cervical spine.



Forward head posture, with posterior cranial rotation and stretching of the infrahyoid muscles has the effect of increasing the activity of the masticatory muscles and cranial extensors, which can result in pain. The muscles of mastication will try to maintain the mandible up (mouth closed, lips touching) and the infrahyoid muscles are trying to bring the mandible down and back so there is a constant fight between muscles that do depression of the mandible and muscles that do elevation of the mandible and that is referred to as parafunction. With the increased isometric muscle contraction of the muscles of elevation, those are the groups of muscles that you have to balance by restoring normal alignment of the craniocervical angle and the cervical lordosis on a stable shoulder girdle. Hence the importance of finding a qualified physical therapist with appropriate certifications in the management of temporomandibular disorders (TMD).